

Dane County EMS Newsletter

May, 2024



A Note to Providers...

We personally wanted to use this space to thank each and every one of you for the care you provide. Traumas and tragedies are an inescapable part of modern life. In addition to what we all read and see in the news, all of you on the front lines of health care gain some level of personal exposure to it all. What you do, matters. HOW you do your job matters even more. If you need time to process the things you see and hear, if you need resources such as peer to peer counseling or just to discuss a case or detail that you may be clinging to, we have you covered. Dane County EMS has resources for you. Just be sure to make your needs known. Asking why things happen, why a particular outcome occurred, or even why you have the reaction that you do to a situation is a healthy way to deal with the rigors of our very important duties. Please remember that everyone processes stressful situations differently and you may find a case/call that is particularly impactful on your headspace while your coworkers see it as a routine call. That is OKAY. If you have medical questions, please feel free to reach out to your service's medical director, or to the three of us Dane County Medical Advisors. On behalf of Dane County EMS staff, stay safe and be well.

Dr. Jeff VanBendegom - jeffvan1@hotmail.com

Dr. Mike Lohmeier - mtlohmei@medicine.wisc.edu

Dr. Nick Wleklinski - Wleklinski@mep.health

Carrie Meier - meier.carrie@danecounty.gov

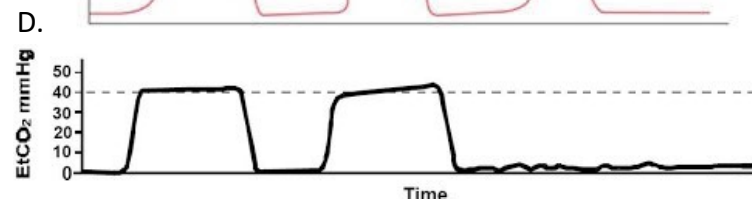
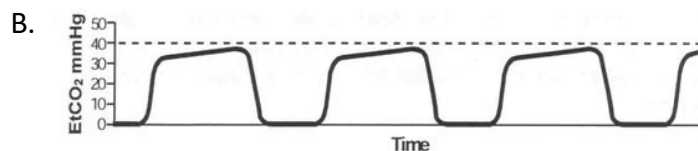
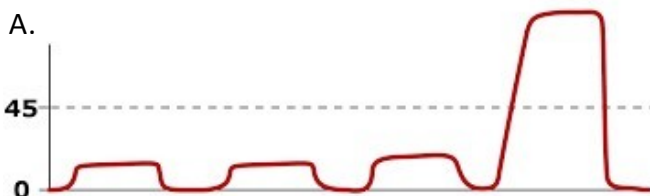
Eric Anderson - anderson.eric@danecounty.gov

Courtney Morency - Morency.courtney@danecounty.gov

May Viz Quiz

Match the capnography tracings with the situation:


1. Normal Waveform
2. Need to start CPR
3. Need to STOP CPR (your have ROSC)
4. Give Narcan



April Viz Quiz Follow Up

- Concerning blunt trauma to the face or head, there are multiple injuries one should consider. Depending on the mechanism of injury, age, and use of blood thinners some injuries are more of a potential problem than others.
- Some more serious injuries to consider in someone that has visual changes with blunt trauma would be intracranial pathology like a brain bleed. In a focused mechanism of injury to the midface or eye some things to consider could also be a traumatic iritis (textbook signs and symptoms would include light sensitivity, headache, loss of vision or change of vision in the affected eye). Something else to consider could be a retrobulbar hematoma a.k.a. a bleed behind the eyeball that's compressing the optic nerve (textbook signs and symptoms would include vision loss, proptosis (a.k.a. the eye bulging forward), inability to move the eyeball of the affected eye).
- In this specific patient the concern is for an orbital floor fracture. This is also called a blowout fracture. A known complication from this type of fracture is the entrapment of the inferior rectus muscle in the maxillary sinus (the muscle that allows the eye to look up).

Congratulation to Susan for winning the April Viz Quiz prize!



Case Study

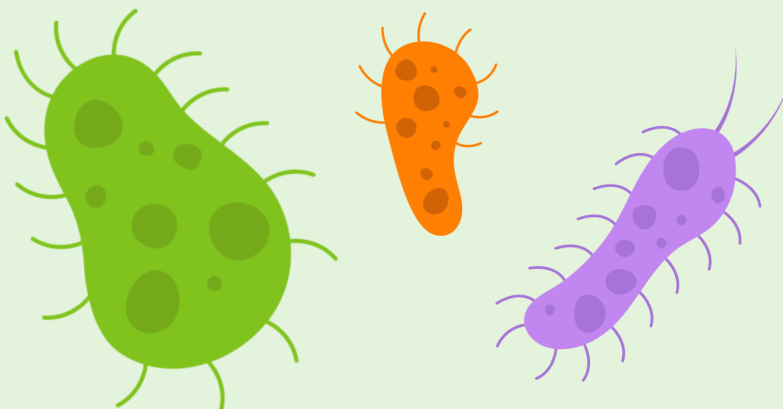
Case: You are called to the residence of an 88 year-old woman for syncope. She reports awakening during the night to use the bathroom. When she got up, she felt weird and next recalls awakening on the ground. Since then, she notes pain across her upper back. The patient denies any prior history of syncope. She has had back pain for many years, but worse since tonight's event. On your arrival, the patient is awake and alert. She looks uncomfortable. Vitals: BP 200/120, HR 90, RR 16, SpO2 95%. Lungs are clear. Heart is regular. The patient's extremities are all cool with decreased cap refill. She is NOT anticoagulated, denies hitting her head, and has no neck pain. What emergent concerns do you have? Is there anything else you can do in the assessment or treatment of this patient?

Aortic dissection: This rare but highly fatal diagnosis should be suspected whenever a patient has syncope along with acute back or scapular pain, OR if there is complaint of chest pain AND a new neurologic deficit. It was first described in an autopsy done on King George II in 1760. The underlying pathology is a tear between two layers of the aorta (the intima and the media). The location from which the dissection emanates influences the presenting symptoms. The prevalence is about 2-3 per 10,000 people. Fatality rate is also dependent on site of dissection (ascending vs descending aorta). Overall, about 50-75% die acutely, with mortality increasing 2% per hour from onset of acute symptoms. Clinical clues – feel for pulses in both arms. Check blood pressure in both arms – a difference of 20 mm Hg or more between arms raises suspicion. Treatment: Starts with simply suspecting the diagnosis! Large-bore IV. EKG. Cardiac monitor. Transport quickly. Blood pressure lowering – often beta-blockers. Ascending dissections require cardiothoracic surgical repair in most cases. Diagnostic testing; CT Angiogram/aortogram of the chest and abdomen. Outcome: In this case, the diagnosis was suspected, CT obtained. Surgery consulted and by mutual agreement surgery was declined and patient admitted to palliative care. Her family was able to visit the patient in the ED before she expired 3 hours after arrival.

Measles Update

See attached for updates and reminders on measles and best practice for operations.

Stay safe!



Upcoming Events and Training

May 15th - UW Health Monthly Training: Psych Emergencies

Register at uwhealth.org/een

May 19th-25th - EMS Week

See attached for food offered at EDs!

May 23rd - DeerGrove EMS Blood Drive

Register to donate [here](#)

June 1st - Survivor Celebration

Email [Courtney](#) to RSVP late

June 19 - UW Health Monthly Training: Trauma Review

Register at uwhealth.org/een

June 3rd-26th - 53rd Annual Emergency Care & Trauma Symposium (Virtual)

Register for sessions [here](#)